

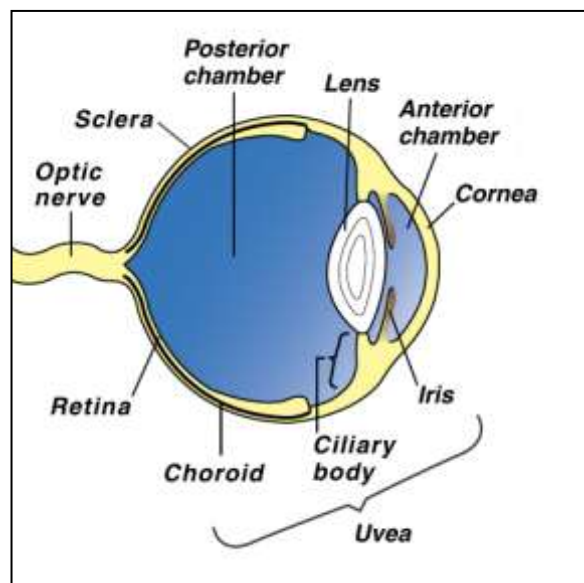


NORTHPARK Animal Hospital

UVEITIS

The uvea comprises the iris, the ciliary body and the choroid within the eye. The choroid is the middle or vascular coat of the eye between the sclera – the fibrous protective outer coat (the white of the eye) and the retina which is the light sensitive surface within the eye.

The iris and the ciliary body together form the anterior uveal tract. The iris is the pigmented membrane behind the cornea (clear part of the eye). It is responsible for the color of the eye. The size of the central perforation or pupil controls the amount of light entering the eye. The ciliary body is a thickened extension of the choroid (vascular tunic of the eye) and connects the choroid and the iris. It produces the aqueous humor important in nutrition of the eye and also in maintaining intra-ocular pressure (IOP). The ciliary body contains muscles and the suspensory ligament supporting the lens within the eye. The ciliary muscles via the suspensory ligament control the shape of the lens and hence its ability to focus images.



Uveitis has a variety of synonyms. If all three structures are involved, (ciliary body, iris and choroid), it is true uveitis or pan-uveitis. If only the ciliary body and the iris are inflamed it is called iridocyclitis or anterior uveitis, while inflammation of the choroid is choroiditis or posterior uveitis.

What are the causes of uveitis?

There are many potential causes of uveitis. Sometimes the true cause is never discovered. Common causes are infection (viral, bacterial, parasitic or fungal), metabolic disease, diabetes mellitus, high blood pressure, toxemia, immune mediated (particularly autoimmune disease where the dog produces antibodies against its own tissue), trauma, lens damage resulting in the leakage of lens protein, and tumors.

What are the signs?

The usual signs of uveitis are severe pain with an intense reddening of the visible parts of the eye. The eye is usually kept shut and most pets avoid bright lights. Cloudiness of the eye may be noticed. Sometimes there is bleeding into the eye. There may be excessive tearing.

How is the condition diagnosed?

Many of the signs of uveitis are similar to glaucoma. With uveitis, IOP is reduced whereas with glaucoma it is raised. Measurement of IOP is often performed to differentiate between the two conditions and is a simple, painless procedure. A thorough examination of the whole of the pet must be performed since generalized illnesses can have uveitis as one of their signs. Often there is a color change of the iris, which may remain permanent. Special procedures such as ultrasound may be used to examine the eye.

Treatment

Treatment is initially aimed at reducing inflammation and providing pain relief. Treatment of uveitis due to trauma can involve repair of any corneal tears or removal of a foreign body in the eye. This may involve referral to a specialist. A combination of drops or ointments combined with tablets may be required.

In order to assess the initial response to treatment, we will need to examine your dog frequently.

Complications

Most cases of uveitis begin to improve within 24 hours. If the eye is very cloudy or if hemorrhage has occurred, this may take a few more days to clear.

Complications are more common after very severe or repeated cases of uveitis. These can involve the development of synechiae and glaucoma. Synechiae are adhesions between the lens and the iris. Glaucoma is an increase in IOP. Both complications may need specialist treatment. Severe uveitis can result in blindness.