



NORTHPARK Animal Hospital

CERVICAL VERTEBRAL INSTABILITY, CERVICAL STENOSIS OR WOBBLER SYNDROME

What is cervical stenosis?

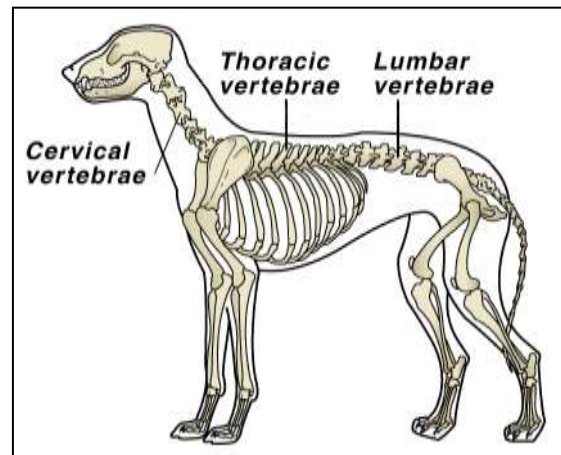
Cervical stenosis is also known as cervical vertebral instability, cervical spondylopathy or Wobbler syndrome. It is due to the compression of the spinal cord, usually at the base of the neck.

How does it affect the dog?

Although the spinal cord compression occurs in the neck, the hind legs may sometimes be affected first. The mildest form of cervical stenosis results in stumbling. This can progress to a wobbly gait, hence the term “Wobbler syndrome”. In severe cases there may be sudden total paralysis of all four limbs.

What causes it?

It may be due to instability of one or more of the vertebrae at the base of the neck (cervical vertebrae) or it may be due to deformity of these vertebrae, which causes pressure on the spinal cord. This damages the nerves transmitting information to the limbs and thus paresis (weakness) or paralysis can occur.



My dog suddenly became paralyzed. Is this part of the disease?

Initially the pressure affects your dog's ability to move naturally and may be difficult to detect. The incoordination, however slight, can put extra stress on the intervertebral discs which act as shock absorbers. If these rupture, excess pressure is put upon the spinal cord and sudden paralysis may result.

I am told that only large breed dogs are affected. Is this true?

Yes, the condition is most prevalent in the Great Dane and the Doberman but Basset Hounds, St Bernard's, Old English Sheepdogs, Borzois and Pointers are also commonly affected.

There appears to be variation of the age of onset based on breed. For example, Great Danes are usually affected when they are young, about 1-3 years of age, whereas Dobermans and other breeds are usually 6-9 years of age before any signs are apparent.

How is the condition diagnosed?

Breed and clinical signs are good indicators of cervical stenosis. With your dog anesthetized, x-rays of the neck will often reveal abnormalities affecting the cervical vertebrae at the base of the neck. Definite diagnosis depends upon myelography. This is a diagnostic technique employing a special radiopaque solution, which is injected into the spinal canal of an anesthetized dog. A series of x-rays are then taken of the spine. The area of pressure is indicated by a thinning of the column of dye at the pressure points.

What is the treatment?

Anti-inflammatory drugs and analgesics are frequently used at the outset but the greatest chance of success lies with surgery, particularly if performed early. Although some dogs respond very well with medication alone, continued long term use can have side effects.

What does surgical treatment involve?

It is important that pressure on the spinal cord is relieved as soon as possible. Medical treatment with anti-inflammatory drugs reduces the pressure due to inflammation but this will not resolve the problem if there is a deformed vertebra or disc material pressing on the spinal cord.

There are several surgical techniques that can be used to relieve this pressure and if the surgery is performed at an early stage, before irreversible damage has occurred, the outlook can be quite good.



Is there a lot of nursing care involved?

Most veterinarians insist on some hospitalization for several days following this surgery. It is important that the dog receives help with walking and must not be allowed to climb steps or stairs for some time once at home.

Call us anytime to discuss specific nursing problems if you would call us.

Is the condition likely to occur again after surgery?

This is dependent on your pet's specific condition. If there is an inherent weakness in the spine, it is possible for the condition to recur at a later date. However, with modern surgical techniques, this is not common.